

LETTER TO THE EDITOR

DENTAL PULP IN MATURE REPLANTED HUMAN TEETH: MORPHOLOGICAL ALTERATIONS AND METALLOPROTEINASES- 2 AND -9, ANNEXIN-5, BCL-2 AND iNOS MODULATION

A. LEONE¹⁻², A. ANGELOVA VOLPONI², ML. UZZO¹, GF. SPATOLA¹, A. JURJUS³
and V. VANDEVSKA–RADUNOVIC⁴

¹*Department of Experimental Biomedicine and Clinical Neurosciences, Section of Histology, University of Palermo, Palermo, Italy;* ²*Department of Craniofacial Development and Stem Cell Biology, King's College, London, UK;* ³*Department of Anatomy, Cell Biology and Physiology, American University of Beirut, Beirut Lebanon;* ⁴*Department of Orthodontics, Institute of Clinical Dentistry, University of Oslo, Oslo, Norway*

Received June 24, 2015 – Accepted October 5, 2015

All authors share the same authorship

Tooth replantation, as a treatment concept, has been subject to controversies regarding the mechanism as well as the various parameters underlying this process. This work aimed to study time-related changes in the pulp of replanted mature human premolars through the changes in the levels of certain factors involved in the underlying mechanisms of pulpal tissue healing after replantation. Eleven experimental mature teeth were extracted, immediately replanted in the original socket and left without any other intervention for 1, 2, 3 and 12 weeks before re-extraction. Three premolars served as control. All specimens were subject to histological analysis and the levels of MMP-2, MMP-9, Annexin V, iNOS and BCL-2 (anti-apoptotic family) were analyzed employing immunohistochemistry. The results showed degradation of the extracellular matrix (ECM), inflammatory cell infiltrate, loss in pulp-dentine interface and loss of odontoblasts in the dental pulp tissue. This was accompanied by increase over time of MMP-9, Annexin V, iNOS and a decrease of BCL-2 and MMP-2, suggesting that apoptosis increased throughout the experimental period.

Dental pulp is a connective tissue that is well vascularized and innervated, capable of limited repair after trauma and/or noxious stimuli (1). Tooth replantation and transplantation are clinical procedures where pulpal tissues undergo temporal disruption of their vascular and neural supply. The initial pulpal reaction may be inflammation,

degeneration of the osteoblast layer and in most severe cases, necrosis (2, 3). However, under favorable conditions, the pulpal tissues may demonstrate revascularization, re-innervation, and formation of reparative dentin. (4-6).

Matrix metalloproteinases (MMP's) are endopeptidases that take part in the degradation

Key words: dental pulp, replanted teeth, morphological alteration

Mailing address: Dr Angelo Leone
BioNec, Section of Histology and Embryology
School of Medicine, University of Palermo
Via del Vespro, 129
90127 Palermo - Italy
Tel +39 0916553581
e-mail: angelo.leone@unipa.it

0393-974X (2015)

Copyright © by BIOLIFE, s.a.s.

This publication and/or article is for individual use only and may not be further reproduced without written permission from the copyright holder.

Unauthorized reproduction may result in financial and other penalties
DISCLOSURE: ALL AUTHORS REPORT NO CONFLICTS OF INTEREST RELEVANT TO THIS ARTICLE.

of extracellular matrix (ECM) components and mediate tissue remodeling in hard tissues such as bone (7). They have been identified in clinically healthy and inflamed pulp tissues (8), suggesting that they participate in the regulation of inflammatory mediators (9). Moreover, vascular cell apoptosis, proliferation, and angiogenesis can also be moderated by MMPs (10), changes that follow the pulp tissue reaction to teeth replantation. In a previous study, we showed that decrease of metalloproteinase activity after orthodontic traction may be an impediment to the regeneration of the ECM and the restoration of dental pulp structure (11).

A well-known hallmark of apoptosis, particularly in the early events, is Annexin V (12). Annexin V is involved in the process of apoptosis following tooth development (13), where apoptosis occurs at different stages of the development as a physiological event. The control of apoptosis as a process is influenced by the interplay between members of the B-cell lymphoma 2 (BCL-2) family, indicating these factors as players in the physiological control of apoptosis (14). BCL-2 is considered to be an anti-apoptotic member of the BCL-2 family and is shown to be an important factor for preventing apoptosis of odontoblasts and promoting dentin damage repair (15).

When a cascade of an immune response is triggered as a consequence of an injury or a noxious factor, the cells of the immune system produce nitric oxide (NO), a short lived highly reactive free radical with cytotoxic properties damaging host tissue. It has been recognized that NO causes induction of apoptosis in human dental pulps (16-18) and was indicated as a factor in the production of tertiary dentin by odontoblasts (19).

The purpose of this study was to investigate time-related changes in the pulp of replanted human premolars through the expression and distribution of MMPs, NO, Annexin V and BCL-2.

MATERIALS AND METHODS

Collection of the material was performed at the Department of Orthodontics, University of Oslo, according to the procedure described in detail by Breivik and Kvam (20). The material was obtained from twelve girls (age: 10.2-19.7 years) and twelve boys (age: 10.2-13.3 years) where extractions of teeth (two or four premolars) were needed as

part of their orthodontic treatment. Experimental teeth were extracted and immediately replanted into the original socket, marked as time point zero (T0) and left without any other intervention for 1, 2, 3 and 12 weeks before re-extraction (T1). Each subject had one premolar extracted as a control at T1. The teeth were fixed in 4% paraformaldehyde (PFA), embedded in paraffin and sectioned at 5 μ m thick sections for further analysis. Approximately half of the sections were stained with haematoxylin and eosin (H&E) and used for histological evaluation in previous studies (3, 21). The rest of the sections were stored at room temperature and some of them used for immunohistochemical analysis in this study.

In this investigation, a total of fourteen mature teeth were used: eleven teeth representing 1 (n=2), 2 (n=2), 3 (n=4) and 12 (n=3) weeks after replantation and three control teeth. The slides were dewaxed and rehydrated by sequential immersion in a graded series of alcohols and transferred into water for 5 min. To inhibit any endogenous peroxidase activity, the slides were treated for 5 min with peroxidase quenching solution in hydrated incubation enclosure at room temperature. Subsequently, the slides were transferred to PBS (Na₂HPO₄, KH₂P0₄, KCl, NaCl pH 7.4 - 7.6) at room temperature. The following protocol was realized using Histostain®-Plus 3rd Gen IHC Detection Kit with DAB chromogen as substrate (Invitrogen). After rinsing with PBS for 4 min, the sections were incubated with a blocking solution for 10 min and then incubated overnight at 4°C with rabbit anti-mouse MMP-9, full-length polyclonal antibody (Chemicon International) diluted 1:100, mouse anti-human MMP-2 monoclonal antibody (Millipore, USA) diluted 1:100, rabbit monoclonal anti Annexin V antibody (Genetex Inc.) diluted 1:100, rabbit monoclonal Anti iNOS antibody (Genetex Inc.) diluted 1:100, mouse monoclonal anti BCL-2 clone 100 antibody (Millipore) diluted 1:100.

After incubation, slides were washed with PBS for 5 min and the sections were incubated with biotinylated secondary antibody for 20 min at room temperature. Unbound antibody was removed by washing (2x with PBS, 5 min each), followed by Streptavidin-Peroxidase conjugate for 10 min. To reveal the reaction DAB chromogen in substrate buffer was added for 5 min and stopped in distilled water. The slides were removed from the water and mounted with one drop of aqueous mounting medium (DAKO, Faramount). Negative controls were performed by omission of primary antibody, and by incubating sections with antiserum saturated with homologous antigen. Finally, the sections were observed with Leica Laborlux S microscope.

Image analysis

The immunohistochemical specimens were examined

using a Leica DM1000 Microscope (Leica Microsystem GmbH Wetzlar, Germany) with a Leica digital photographic system. Each sample was analyzed with double-blind system and two different operators. Moreover, the results were compared to an image analysis obtained from TIFF files. Adobe Photoshop CS6 extended (Adobe System Inc, San Jose, CA, USA) was used to elaborate images and perform an image analysis (22, 23). The images were analyzed in CMYK color profile, using the yellow channel for a best linear response to color intensity (24). All the images, converted in a gray scale inverted images, were analyzed and a range of 0-255 value was detected, where 0 marked the maximum black value and 255, marked the maximum white value. The colorimetric analysis was performed for the entire pulp tissue surface and the values were expressed in the following scale range: “+” (0-50); “++” (51-100); “+++” (101-150); “++++” (151-200); “+++++” (2001-255) (24).

RESULTS

Control teeth

Teeth stained with H&E (Fig.1 A1), exhibit normal histological features of well organized connective pulp tissue (P) with visible blood vessels (BV) and tubular dentin (D). Distinct odontoblast layer (Ob) was present adjacent to the pulp-dentin border. Immunohistochemical staining did not show particular accumulation, showing homogeneous distribution throughout the pulp tissue (Fig B1-F1).

Quantitatively, the expression of MMP-2 and BCL-2 was strongest, while MMP-9, Annexin V and iNOS showed low colorimetric staining (Table I).

1-3 weeks

The results obtained from teeth extracted 1, 2 and 3 weeks after replantation were similar in histological changes, accumulation pattern and quantitative expression of the markers. Therefore, these time points were treated as one experimental group. The pulp tissue (P) showed irregular fibrous matrix, loss of normal vasculature and abnormal odontoblast layer (Fig.1 A2). The pulp-dentine junction showed areas of interruption (arrows) with infiltration of inflammatory cells (circled areas). Some vacuolization was present (Fig 1 E2 *asterisk) next to the pulp-dentin junction.

Immunohistological analysis revealed homogeneous distribution of immunopositive cells throughout the pulp tissue, with no particular

accumulation (Fig. 1 B2, C2, E2, F2), except for the Annexin V (Fig. 1 D2), where more positive cells (arrows) were present in the odontoblast area (Ob) next to the pulp-dentine junction.

The intensity of the staining for MMP-2 and BCL2 was decreased compared to the control group, while the opposite was observed for MMP-9, Annexin V and iNOS (Table I).

12 weeks

The pulp was highly vacuolated, particularly evident next to the enamel-dentin junction with possible fluid accumulation in the interface (Fig. 1 A3 * asterisk area). Edema and inflammatory cells were visible throughout the pulp tissue (Fig. 1 A3), as well as red blood cells. The odontoblast layer was lost and gap was evident in the pulp-dentine junction area (Fig. 1 A3, D3, F3-square), leaving no clear alignment or histological features of odontoblasts.

Immunopositive cells for MMP 2, MMP9, iNOS and BCL2 were distributed throughout the pulp tissue, with no particular accumulation (Fig. 1 B3, C3, E3, F3), while Annexin V (Fig. 1 D3), positive cells (arrows) were more present in the odontoblast area (Ob) next to the pulp-dentine junction.

The intensity of the staining for MMP-9, Annexin V and iNOS was similar to the previous experimental periods, and higher than the control teeth. BCL2 showed further decrease in staining, while no changes were observed in MMP-2 (Table I).

DISCUSSION

Replantation of teeth is followed by a series of reactive alterations of dental pulp tissue. This is

Table I. Quantification of colorimetric staining.

	0	3 week	12 week
MMP2	+++	+	+
MMP9	+	++	+++
ANNEXINA V	+	+++	++
iNOS	+	+++	+++
BCL2	+++	++	+

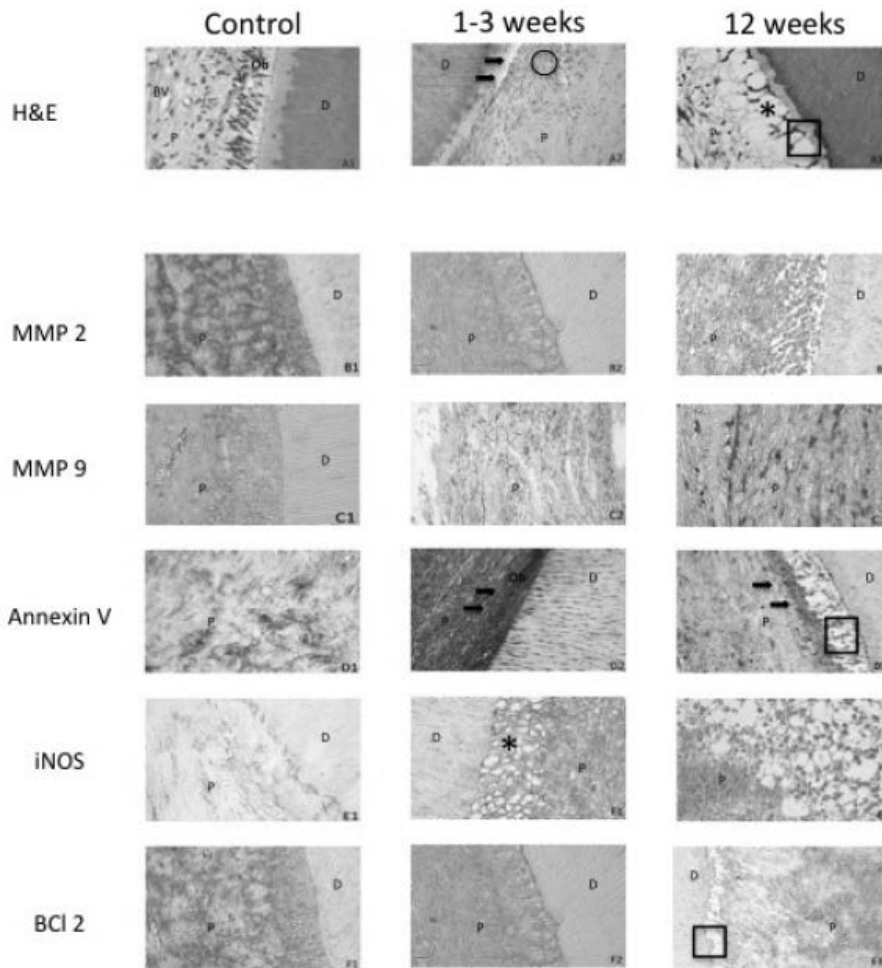


Fig. 1. Histological alterations and expression of different markers of dental pulp tissue in human replanted teeth at different time points. **A**) H&E staining of dental pulp tissue in control (A1) shows normal histological features of the dental pulp tissue (P), visible blood vessels (BV) and tubular dentin (D). Distinct odontoblast layer (Ob) was adjacent to the pulp-dentin border. Replanted teeth after 1-3 weeks (A2) showed irregular fibrous matrix in the pulp tissue (P), loss of normal vasculature and abnormal odontoblast layer. (The pulp-dentine junction showed areas of interruption (arrows) with infiltration of inflammatory cells (circle areas)). At 12 weeks (A3), the pulp (P) was highly vacuolated, particularly evident next to the enamel-dentin junction with possible fluid accumulation in the interface (* asterisk area). The odontoblast layer was lost and gap was evident in the pulp-dentine junction area (square). **B**) The immunohistochemical reaction of MMP-2. Decrease in the difference between Control (B1), 1-3 weeks (B2) and 12 weeks (B3) time points was noticeable. There is a significant decrease of MMP-2 with time in parallel to an increase of vacuolization of the pulp. **C**) Immunohistochemical reaction of MMP-9. Note the significant increase in MMP-9 stain after 1-3 weeks (C2) compared to Control (C1). MMP-9 continued to increase with time (C3). **D**) Immunohistochemical reaction of Annexin V. There was noticeable increase in Annexin V positive cells in time from Control (D1) to 1-3 weeks (D2), where there was a significant positive staining in the odontoblast layer (Ob), (arrows). This decreased in the 12 weeks group (D3-arrows), followed by noticeable gap at pulp-dentine junction (square). **E**) Immunohistochemical reaction of induced nitric oxide (iNOS). The immunopositive cells increased through time (E1-E3) with vacuolisation in the pulp-dentine junction starting at 1-3 weeks time point (D2-asterisk). **F**) Immunohistochemical reaction of BCL-2. The BCL-2 expression decreased through time (F1-3), with more evident gap in the pulp dentin junction (D3-square), indicating advanced degenerating changes in the dental pulp at this time point. (Images taken at x400).

due to the severed vascular and nerve supply that accompanies the procedure and consequently triggers inflammatory and degenerative changes in the dental pulp (3). Subsequent healing of the pulp takes place in a high percentage of replanted immature teeth, but also, to a lesser extent, in mature teeth (6). A number of investigations have attempted to examine the underlying biological mechanisms determining the healing process, but the majority is descriptive and almost exclusively carried out on animal teeth (25-28). Therefore this histological material provides a unique opportunity to study the time-related pulpal tissue changes after replantation of mature human teeth.

A previous study showed that degradation of dental pulp tissue, losing its anatomical "order" and disturbances in the odontoblastic layer, as well as severed vascularization of the dental pulp tissue was noticeable within 3 weeks of replantation of mature human premolars (3). This was confirmed in the present study, where the histological appearance of the pulp was noticeably different from that of the control teeth showing signs of inflammation and partial loss of the normal odontoblastic layer. Such a reaction was aggravated by a later time point (12 weeks), leading to more dramatic changes due to inflammatory reaction followed by fibrosis and vacuolization of the dental pulp tissue, loss of a distinct odontoblast layer and a consequent degeneration of the dental pulp tissue. There was a loss of distinct blood vessels, usually present in a healthy pulp tissue, but a presence of blood cells, as a consequence of bleeding, was noticeable.

In order to study the main mechanisms that underlie the changes, we assumed the role of inflammation and apoptosis as being main processes following the replantation of teeth, causing changes in the dental pulp tissue.

Inflammatory cells infiltrated the pulp tissue after 3 weeks and increased more by 12 weeks. This was followed by an increase in MMP-9 through the different time points, as a result of degradation of the extracellular matrix. The present results confirm the data of previous reports on the increase in MMP-9 during inflammatory processes (29, 30).

On the other hand, there was less presence of MMP-2 in the dental pulp with the progression of time. Although this observation was in contradiction

to previous reports (8), it was in accordance with other studies where MMP-2 was proposed to be able to release active Tumor Growth Factor β 2 (TGF- β 2) during noxious stimulated conditions (such as caries), which can then stimulate diverse repair processes (31).

Further studies focusing on TGF- β 2 and other factors such as Tissue Inhibitors of Metalloproteinases (TIMPS) may explain the results, as these inhibitors might act ambiguously at times, favoring the activation, or inhibiting the MMP-2 (8, 32).

The observed morphological alterations of the pulp tissue suggested an increase in apoptosis. This has been confirmed by an increase in Annexin V, well-known hallmark of apoptosis (12), and the decrease in the anti-apoptosis protein BCL-2, recently indicated as an important factor where its over expression can prevent odontoblastic apoptosis and promote dentin damage repair (15). Annexin V increased from day zero (+1) to week 3 (+3) then decreased (+2) by 12 weeks when necrotic changes were detected.

The increase in apoptosis is closely connected to the inflammatory processes and response of the dental pulp, confirmed and influenced by the increase of MMP-9 and iNOS which were increased over time. iNOS is a recognized mediator and regulator of the inflammatory response (16). NO is produced by nitric oxide synthase (NOS) which is abundantly expressed in human dental pulp cells and can be cytotoxic to these cells. It induces apoptosis and increases the number of Annexin V positive human dental pulp cells. It was suggested that NO induces apoptosis of human dental pulp cells (HDPC's) through the mitochondria dependent pathway (18). This NO-induced apoptosis could be influenced by modulation of BCL-2 (an anti-apoptotic BCL-2 family) in human dental pulp cells (17). Further studies including these factors might contribute to better understanding of the cascade of events that follow the triggering of the apoptosis. In addition, phagocytosis of the apoptotic odontoblasts and other pulp cells by scavenger cells may result in decrease of Annexin V level over time.

In our study we have shown a steady decrease in time in BCL-2, explaining the most obvious histological change in the dental pulp tissue - the loss of odontoblastic layer. BCL-2 has been indicated

as one of the important factors to promote dentin damage repair, when BCL-2 overexpression prevented artificial cavity-induced odontoblast apoptosis (15).

A study of the periodontal membrane proliferation, possible stem cell migration and the following changes could help in elucidating the homeostasis of renewing tooth tissues and maintaining a balance between cell proliferation, cell differentiation, and cell death (33).

In conclusion, the spectrum of histological alterations in replanted mature teeth indicate an ongoing inflammatory process depicted by the inflammatory cell infiltration leading to (i) ECM degradation through the increase and maintenance of high levels of MMP-9, (ii) increase in apoptosis, expressed by the increase of Annexin V and decrease of BCL-2, (iii) the loss of odontoblast layer, and (iv) eventually necrosis by 12 weeks of replantation. This study of mature human replanted teeth has its own limitations due to the small number of teeth and lack of long-term data. Furthermore, tracking the histological changes in the periodontal ligament might provide valuable data, however this was not possible in the present material.

REFERENCES

- Smith AJ. Pulpal responses to caries and dental repair. *Caries Res* 2002; 36:223-32.
- Rungvechvuttivittaya S, Okiji T, Suda H. Responses of macrophage-associated antigen-expressing cells in the dental pulp of rat molars to experimental tooth replantation. *Arch Oral Biol* 1998; 43:701-10.
- Fiane JE, Breivik M, Vandevska-Radunovic V. A histomorphometric and radiographic study of replanted human premolars. *Eur J Orthod* 2014; 36(6):641-8.
- Skoglund A, Tronstad L, Wallenius K. A microangiographic study of vascular changes in replanted and autotransplanted teeth of young dogs. *Oral Surg Oral Med Oral Pathol Oral Radiol Endod* 1978; 45:17-28.
- Kvinnslund I, Heyeraas KJ, Byers MR. Regeneration of calcitonin gene-related peptide immunoreactive nerves in replanted rat molars and their supporting tissues. *Arch Oral Biol* 1991; 36:815-26.
- Andreasen JO, Paulsen HU, Yu Z, Bayer T, Schwartz O. A long-term study of 370 autotransplanted premolars. Part II. Tooth survival and pulp healing subsequent to transplantation. *Eur J Orthodont* 1990; 12:14-24.
- Paiva KB, Granjeiro JM. Bone tissue remodeling and development: focus on matrix metalloproteinase functions. *Arch Biochem Biophys* 2014; 561:74-87.
- Accorsi-Mendonça T, Nogueira Leal Silva EJ, Marcaccini AM, Gerlach RF, Roncato Duarte KM, Souza Pardo AP, Peres Line SR, Zaia AA. Evaluation of gelatinases, tissue inhibitor of matrix metalloproteinase-2, and myeloperoxidase protein in healthy and inflamed human dental pulp tissue. *J Endod* 2013; 39(7):879-82.
- Gusman H, Santana RB, Zehnder M. Matrix metalloproteinase levels and gelatinolytic activity in clinically healthy and inflamed human dental pulps. *Eur J Oral Sci* 2002; 110 (5):353-7.
- Li Z, Chen Q, Jin M, Yang F, Zhu J, Xiao Q, Zhang L. Matrix metalloproteinases: inflammatory regulators of cell behaviors in vascular formation and remodeling. *Mediators Inflamm* 2013; doi: 10.1155/2013/928315.
- Leone A, Mauro A, Spatola GF, et al. MMP-2, MMP-9, and iONS Expression in Human Dental Pulp Subjected to Orthodontic Traction. *Angle Orthod* 2009; 79:1119-25.
- Marder LS, Lunardi J, Renard G, et al. Production of recombinant human annexin V fed-batch cultivation. *BMC Biotechnol* 2014; 14(1):14-33.
- Bronckers AL, Goei SW, Dumont E, Lyaruu DM, Wöltgens JH, Van Heerde WL, Reutelingsperger CP, Van den Eijnde SM. In situ detection of apoptosis in dental and periodontal tissues of the adult mouse using annexin-V-biotin. *Histochem Cell Biol* 2000; 113(14):293-301.
- Czabotar PE, Lessene G, Strasser A, Adams JM. Control of apoptosis by the BCL-2 protein family: implications for physiology and therapy. *Nat Rev Mol Cell Biol* 2014; 15(1):49-63.
- Zhang W1, Ju J. Odontoblast-targeted Bcl-2 overexpression promotes dentine damage repair. *Arch Oral Biol* 2012; 57(3):285-92.
- Korhonen R, Lahti A, Kankaanranta H, Moilanen E. Nitric oxide production and signaling in inflammation. *Curr Drug Targets Inflamm Allergy* 2005; 64:749-74.

17. Park SY, Jeong YJ, Kim SH, Jung JY, Kim WJ. Epigallocatechin gallate protects against nitric oxide-induced apoptosis via scavenging ROS and modulating the Bcl-2 family in human dental pulp cells. *J Toxicol Sci* 2013; 38(3):371-8.
18. Park MY, Jeong YJ, Kang GC, Kim SH, Chung HJ, Jung JY, Kim WJ. Nitric oxide-induced apoptosis of human dental pulp cells is mediated by the mitochondria-dependent pathway. *Korean J Physiol Pharmacol* 2014; 18(1):25-32.
19. Yasuhara R, Suzawa T, Miyamoto Y, Wang X, Takami M, Yamada A, Kamijo R. Nitric oxide in pulp cell growth, differentiation, and mineralization. *J Dent Res* 2007; 86(2):163-68.
20. Breivik M, Kvam E. Evaluation of histologic criteria applied for description of pulp reactions in replanted human premolars. *Scand J Dent Res* 1977; 85:392-95.
21. Breivik M. Human odontoblast response to tooth replantation. *Eur J Orthod* 1981; 3:95-108.
22. Lehr HA, Mankoff DA, Corwin D, Santeusanio G, Gown AM. Application of photoshop-based image analysis to quantification of hormone receptor expression in breast cancer. *J Histochem Cytochem* 1997; 45(11):1559-65.
23. Kirkeby S, Thomsen CE. Quantitative immunohistochemistry of fluorescence labelled probes using low-cost software. *J Immunol Methods* 2005; 301(1-2):102-13.
24. Pham NA, Morrison A, Schwock J, Aviel-Ronen S, Iakovlev V, Tsao MS, Ho J, Hedley DW. Quantitative image analysis of immunohistochemical stains using a CMYK color model. *Diagn Pathol* 2007; 27:2-8.
25. Öhman A. Healing and sensitivity to pain in young replanted human teeth. An experimental and histological study. *Odontol Tidsk* 1965; 73:166-227.
26. Ohshima H, Nakakura-Ohshima K, Yamamoto H, Maeda T. Alteration in the expression of heat shock protein (Hsp) 25-immunoreactivity in the dental pulp of rat molars following tooth replantation. *Arch Histol Cytol* 2001; 64:425-37.
27. Schwartz O, Andreasen J O. Allo- and autotransplantation of mature teeth in monkeys: a sequential time-related histoquantitative study of periodontal and pulpal healing. *Dent Traumatol* 2002; 18:246-61.
28. Ogawa R, Saito C, Jung H S, Ohshima H. Capacity of dental pulp differentiation after tooth transplantation. *Cell Tissue Res* 2006; 326:715-24.
29. Leone A, Uzzo ML, Rappa F, Abdallah Hajj Hussien I, Gerbino A, Spatola GF, Jurjus A. Immunohistochemical expression of apoptotic factors, cytokeratins, and metalloproteinase-9 in periapical and epithelialized gingival lesions. *Folia Histochem Cyto* 2012; 50(4):497-503.
30. Tsai CH, Chen YJ, Huang FM, Su YF, Chang YC. The upregulation of matrix metalloproteinase-9 in inflamed human dental pulps. *Journal Endod* 2005; 31(12):860-62.
31. Charadram N1, Farahani RM, Harty D, Rathsam C, Swain MV, Hunter N. Regulation of reactionary dentin formation by odontoblasts in response to polymicrobial invasion of dentin matrix. *Bone* 2012; 50(1):265-75.
32. Nakata K1, Yamasaki M, Iwata T, Suzuki K, Nakane A, Nakamura H. Anaerobic bacterial extracts influence production of matrix metalloproteinases and their inhibitors by human dental pulp cells. *J Endod* 2000; 26(7):410-13.
33. Sato K, Muramatsu T, Tsuchiya Y, Masaoka T, Enokiya Y, Hashimoto S, Shimono M. Proliferation, migration and apoptosis of periodontal ligament cells after tooth replantation. *Oral Dis* 2010; 16:263-8.